


LONG-TERM EFFECTS OF MULTIMODALITY LASER THERAPY IN PATIENT WITH DRUSENOID PIGMENT EPITHELIAL DETACHMENT

Takhchidi KhP, Takhchidi NKh, Kasmyrina TA, Mahno NA 


Pirogov Russian National Research Medical University, Moscow, Russia

Drusenoid pigment epithelial detachment is a condition characterized by separation of the retinal pigment epithelium from the underlying Bruch's membrane due to formation of drusenoid deposits. The disorder represents the intermediate stage of the age-related macular degeneration, and is a risk factor for the age-related macular degeneration progression to late stage characterized by geographic atrophy, which results in the irreversible central vision loss. Management of patients with this disorder is in most cases limited to follow-up. The feasibility of using the multimodality low power mode laser therapy for treatment of drusenoid pigment epithelial detachment is reported. The results of laser photocoagulation of the retina demonstrate the morphological and functional recovery: retinal pigment epithelial detachment sealing, improvement of visual function, and restored retinal architecture.

Keywords: age-related macular degeneration, drusenoid pigment epithelial detachment, retina, micropulse laser

Author contribution: Takhchidi KhP — study concept and design, manuscript editing; Takhchidi NKh — literature analysis; Kasmyrina TA — laser therapy; Mahno NA — data acquisition and processing, manuscript writing.

Compliance with ethical standards: the patients submitted the informed consent to laser therapy and personal data processing.

 **Correspondence should be addressed:** Nadezhda A. Mahno
Volokolamskoe shosse, 30, korp. 2, Moscow, 123182, Russia; nadezda.mahno7@gmail.com

Received: 24.11.2021 **Accepted:** 16.12.2021 **Published online:** 29.12.2021

DOI: 10.24075/brsmu.2021.067

ОТДАЛЕННЫЕ РЕЗУЛЬТАТЫ ПРИМЕНЕНИЯ КОМБИНИРОВАННОГО ЛАЗЕРНОГО ЛЕЧЕНИЯ ДРУЗЕНОИДНОЙ ОТСЛОЙКИ РЕТИНАЛЬНОГО ПИГМЕНТНОГО ЭПИТЕЛИЯ

Х. П. Тахчиди, Н. Х. Тахчиди, Т. А. Касмырина, Н. А. Махно 

Российский национальный исследовательский медицинский университет имени Н. И. Пирогова, Москва, Россия

Друзеноидная отслойка ретинального пигментного эпителия — патологическое состояние, при котором ретинальный пигментный эпителий отделяется от подлежащей мембраны Бруха вследствие образования и накопления друзеноидного материала. Заболевание представляет собой промежуточную стадию возрастной макулярной дегенерации, является фактором риска прогрессирования возрастной макулярной дегенерации до поздней стадии с развитием географической атрофии, что приводит к необратимой потере центрального зрения. В основном ведение пациентов с данной патологией сводится к динамическому наблюдению. Представлена возможность использования комбинированного лазерного лечения с низкоэнергетическими параметрами при лечении друзеноидной отслойки ретинального пигментного эпителия сетчатки. Полученные результаты применения лазерной коагуляции сетчатки свидетельствуют о восстановлении морфофункциональных показателей: ликвидации отслойки ретинального пигментного эпителия, повышении зрительных функций и восстановлении микроархитектоники сетчатки.

Ключевые слова: возрастная макулярная дегенерация, друзеноидная отслойка ретинального пигментного эпителия, сетчатка, микроимпульсное лазерное воздействие

Вклад авторов: Х. П. Тахчиди — концепция и дизайн исследования, редактирование текста; Н. Х. Тахчиди — анализ литературных данных; Т. А. Касмырина — лазерное лечение пациента; Н. А. Махно — сбор и обработка материала, написание текста.

Соблюдение этических стандартов: от пациента получено добровольное информированное согласие на лазерное лечение и обработку персональных данных.

 **Для корреспонденции:** Надежда Александровна Махно
Волоколамское шоссе, д. 30, корпус 2, г. Москва, 123182, Россия; nadezda.mahno7@gmail.com

Статья получена: 24.11.2021 **Статья принята к печати:** 16.12.2021 **Опубликована онлайн:** 29.12.2021

DOI: 10.24075/vrgmu.2021.067

Currently, age-related macular degeneration (AMD) is among the leading causes of the irreversible central vision loss, occurring predominantly in the elderly. According to literature, the prevalence of AMD among individuals aged 45–85 is 8.96%, with a predominance of the early stages of the disease (8.01%) [1].

In accordance with the generally accepted classification of the Age-Related Eye Disease Study (AREDS), AMD is subdivided into four categories. The AREDS Category 1 (no AMD) is characterized by no drusen or small drusen of less than 63 μm in diameter. The AREDS Category 2 (early stage AMD) corresponds to numerous small drusen, and/or a small number of medium-sized drusen of 63–124 μm in diameter, or initial changes in the retinal pigment epithelium (RPE). The AREDS Category 3 (intermediate stage AMD) is characterized by numerous medium-sized drusen, and/or one large druse of more than 125 μm in diameter, or RPE atrophy, not affecting

the retinal center. The AREDS Category 4 (late stage AMD) is characterized by atrophy of RPE and choriocapillaris layer in the retinal center, and/or neovascular maculopathy [2].

Drusenoid pigment epithelial detachment (DPED), in which RPE and its basement membrane are separated from the inner collagen layer of the underlying Bruch's membrane due to formation and accumulation of drusenoid material, represents the intermediate stage of AMD. This form of PED was originally described by A. G. Casswell in 1985 [3, 4].

To date, pathophysiological mechanisms of DPED have not been fully explored. It is believed that this disorder results from the gradual increase and merging of the large number of pre-existing soft drusen, which results in the focal retinal detachment of at least 350 μm in diameter. With increasing DPED, the prolonged dissociation between the RPE cells and the Bruch's membrane/choriocapillaris complex leads on the one hand to the RPE cells' migration into the outer retinal layer,

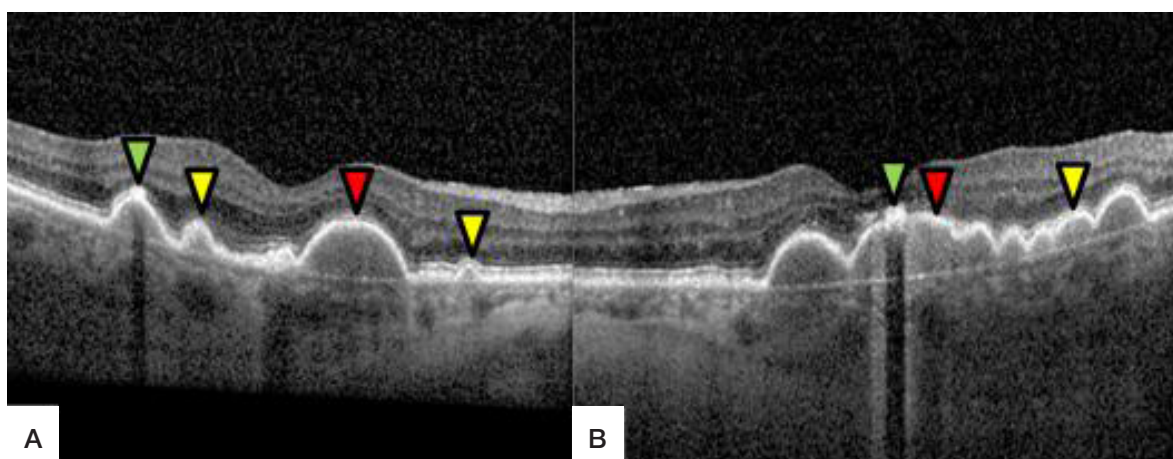


Fig. 1. Spectral-domain optical coherence tomography image of the fovea. **A.** Right eye: RPE detachment (red arrow) with the height of 166 μm and the length of 1126 μm , with homogeneously hyperreflective deposits. Coalescent soft drusen (yellow arrow), accumulation of subretinal hyperreflective deposits (green arrow). **B.** Left eye: RPE detachment (red arrow) with the height of 173 μm and the length of 2348 μm , with homogeneously hyperreflective deposits. Coalescent soft drusen (yellow arrow), accumulation of subretinal hyperreflective deposits (green arrow)

and on the other hand to these cells' apoptosis. The long-lasting DPED, associated with the decreased number and alteration of RPE cells, results in photoreceptor dysfunction and subsequent atrophy. Eventually, in case of DPED collapse, the zone of complete RPE atrophy is registered, with the outer neurosensory retina atrophy [5, 6].

In case of the long-lasting DPED with its subsequent regression, the most common symptoms are as follows: decreased visual acuity, metamorphopsia, difficulty or inability to read up close. However, RPE detachment, identified at an early stage, is characterized by preserved visual functions [5–8].

The use of the spectral-domain optical coherence tomography (SD-OCT) in morphometric assessment of the retinal layer changes in patients with DPED made it possible to distinguish the risk factors for the disease progression, such as height, volume, and diameter of the detached RPE, as well as the presence of intraretinal and subretinal hyperreflective material above the RPE detachment. These risks were studied with regard to DPED located within 500 μm of the fovea [6, 7].

Currently, there are no efficient and safe treatment methods for DPED. If this disorder is diagnosed, the management of patients is in most cases limited to follow-up. However, progression to late AMD is observed in the natural course of the disease within 5 years (42% of cases), with the development of geographic atrophy in the macular zone (19% of cases), which results in irreversible vision loss, as well as in declined quality of life, disability, and poor work ability prognosis [3, 7, 8].

Conservative treatment, which involves the use of antioxidant medications, vitamins and minerals, fails to prevent the AMD progression to advanced stages, which was confirmed by research, and requires the constant use of these medications throughout the patient's life [9].

The majority of studies on assessing the efficacy and safety of using laser technologies in patients with intermediate AMD were focused mostly on finding ways to slow down the disease progression and to reduce the number of various soft drusen types [10–15].

With regard to the high risk of DPED progression to late AMD, with subsequent significant decline in the patients' visual functions, finding the efficient and safe treatment method for this disorder is relevant. The study was aimed to demonstrate and assess the long-term morphological and functional effects of multimodality laser therapy in a patient with DPED, observed during the 5-year follow-up period.

Clinical case

In June 2017, patient Sh. aged 74 presented with complaints of diminished visual acuity in both eyes, metamorphopsia, and trouble with close-up reading using both eyes at the Research Center of Ophthalmology, Pirogov Russian National Research Medical University. According to medical history, the above symptoms have been troubling the patient for a year. In 2015, cataract surgery, phacoemulsification and intraocular lens implantation, was performed in the right and left eye.

Once admitted to the Center, the patient underwent a comprehensive ophthalmic examination, which included the standard diagnostic tests (visometry for uncorrected visual acuity (UCVA) and best corrected visual acuity (BCVA), indirect ophthalmoscopy with a MaxField indirect lens (Ocular Inc.; USA)), specific assessment methods (microperimetry (MAIA microperimeter, CenterVue Inc.; Italy), SD-OCT, and optical coherence tomography angiography (OCTA) performed using a Spectralis HRA+OCT, OCT-2 module at 85,000 Hz (Heidelberg Engineering, Inc.; Germany)).

Laser photocoagulation was performed with the IRIDEX IQ 577 ophthalmic laser system (IRIDEX Corporation, MountainView; USA).

During the initial assessment the patient complained of diminished visual acuity in both eyes, metamorphopsia, and trouble with close-up reading using both eyes; UCVA of the right eye (OD) was 0.3; BCVA was 0.7 OD, and those of the left eye (OS) were 0.2 and 0.7, respectively. According to microperimetry, the average central retinal sensitivity was 23.3 dB OD and 21.6 dB OS.

Slit lamp biomicroscopy and indirect ophthalmoscopy in both eyes (OU) showed that the anterior segment was intact; the well-centered intraocular lens was in the capsular bag. The optic disc was pale pink, with well-defined margins. Hypertensive angiopathy was revealed. There were numerous prominent small yellowish round-shaped lesions with well-defined margins in the macular zone. In the foveal zone, expanding downwards into the parafoveal region, there was a large prominent pale-yellow oval-shaped lesion 1.5 times the diameter of the optic disc with blurry margins and redistribution of pigment, surrounded by large yellowish lesions with blurry margins. Retinal periphery was intact.

SD-OCT OD revealed macular deformation. In the foveal zone, the RPE detachment was visible with the height of 166 μm and the length of 1126 μm , with downward expansion into

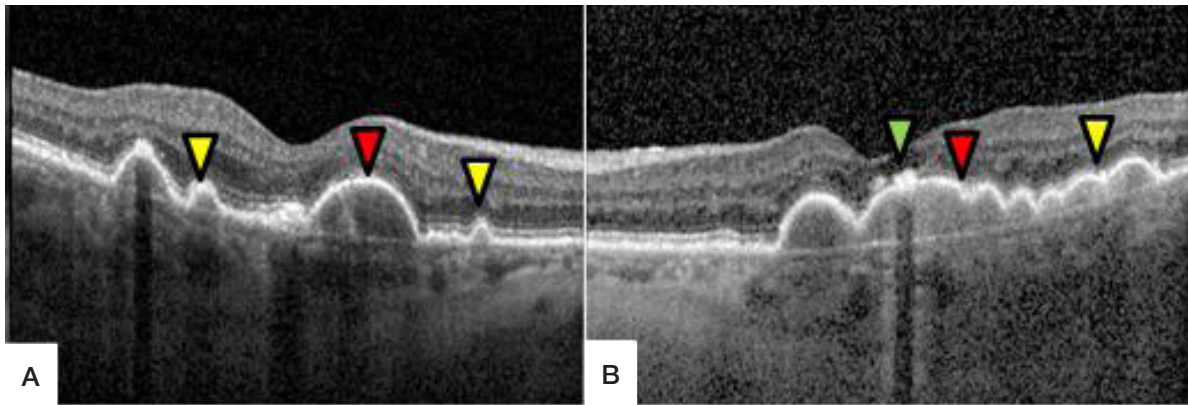


Fig. 2. Spectral-domain optical coherence tomography image of the fovea. **A.** Right eye: RPE detachment (red arrow) with the height of 164 μm and the length of 1081 μm , with homogeneously hyperreflective deposits. Coalescent soft drusen (yellow arrow), accumulation of subretinal hyperreflective deposits (green arrow). **B.** Left eye: RPE detachment with the height of 154 μm and the length of 2286 μm , with homogeneously hyperreflective deposits. Coalescent soft drusen (yellow arrow), accumulation of subretinal hyperreflective deposits (green arrow)

the parafoveal region with the height of 218 μm and the length of 1852 μm , with homogeneously hyperreflective deposits, together with the undulating RPE line, and the coalescent soft drusen up to 125 μm in diameter. Subretinal hyperreflective deposits were found above the detached RPE (Fig. 1A).

SD-OCT OS revealed macular deformation. In the foveal zone, the RPE detachment was visible with the height of 173 μm and the length of 2348 μm , with downward expansion into the parafoveal region with the height of 190 μm and the length of 1039 μm , with homogeneously hyperreflective deposits, together with the undulating RPE line, and the coalescent soft drusen up to 125 μm in diameter. Subretinal hyperreflective deposits were found above the detached RPE (Fig. 1B).

OCTA image (OU) analysis revealed no evidence supporting the choroidal neovascularization.

The following diagnosis was established based on the patient's complaints, medical history, and the results of the comprehensive ophthalmic examination: OU Age-related macular degeneration, dry form, intermediate stage (according to AREDS classification). Drusenoid pigment epithelial detachment. Pseudophakia.

It was decided to perform the multimodality laser therapy, which included grid laser photocoagulation with the lowest possible energy settings to form the first degree coagulum. After 10 days the patient received three sessions of micropulse laser therapy (every four weeks). Grid laser photocoagulation was performed using the following settings: wavelength 577 nm, power 50 mW, pulse duration 0.1 s, spot size 100 μm ; coagula were applied throughout the area of the detached RPE, except avascular zone, with a spacing of 150 μm . Micropulse laser therapy was performed with the following settings: wavelength 577 nm, burst duration 30 ms, micropulse duration 50 μs , pulse ratio 4.7%, spot size 100 μm , power 50 mW; coagula were applied throughout the area of the detached RPE, the avascular zone was avoided.

One month after the multimodality laser therapy the patient reported the improvement of visual acuity, however, metamorphopsia persisted.

Ophthalmic examination showed that UCVA OD was 0.3, BCVA OD had improved to 0.8, UCVA OS had improved to 0.3, and BCVA OS was 0.7. According to micropirometry, the average central retinal sensitivity had improved to 24.1 dB OD, and to 23.0 dB OS. Slit lamp biomicroscopy and indirect ophthalmoscopy OU revealed no improvement: in the foveal zone, expanding downwards into the parafoveal region, there was still a large prominent pale-yellow oval-shaped lesion 1.5 times the diameter of the optic disc with blurry margins and

redistribution of pigment, surrounded by the large yellowish lesions with blurry margins; the lightly pigmented coagula were visible across the surface of the detached RPE.

According to SD-OCT OD, the macular deformation persisted, and the RPE detachment reduction was observed. In the foveal zone, the height of the RPE detachment reduced from 166 to 164 μm , and the RPE detachment length reduced from 1126 to 1081 μm . In the lower parafoveal region the height reduced from 218 to 211 μm , and the RPE detachment length reduced from 1852 to 1826 μm . The homogeneously hyperreflective deposits, together with the undulating RPE line, and the coalescent soft drusen up to 125 μm in diameter were found below the detached RPE. Subretinal hyperreflective deposits were found above the detached RPE (Fig. 2A).

According to SD-OCT OS, the macular deformation persisted, and the RPE detachment reduction was observed. In the foveal zone, the height of the RPE detachment reduced from 173 to 154 μm , and the RPE detachment length reduced from 2348 to 2286 μm . In the lower parafoveal region the height reduced from 190 to 171 μm , and the RPE detachment length reduced from 1039 to 982 μm . The homogeneously hyperreflective deposits, together with the undulating RPE line, and the coalescent soft drusen up to 125 μm in diameter were found below the detached RPE. Subretinal hyperreflective deposits were found above the detached RPE (Fig. 2B).

Three months after the laser treatment on the follow-up examination the patient reported the improvement of visual acuity, no metamorphopsia, and no trouble with the close-up reading. Ophthalmic examination showed that UCVA OD and OS was stable (0.3); BCVA OD and OS was 0.8. The average central retinal sensitivity was stable (24.1 dB OD, 23.4 dB OS). Slit lamp biomicroscopy and indirect ophthalmoscopy OU revealed the following features: small yellowish round-shaped lesions with well-defined margins in the macular zone, sporadic large yellowish lesions with blurry margins, redistribution of pigment; the lightly pigmented coagula were visible, the DPED was completely regressed.

SD-OCT OD and OS revealed the restored macula, the completely regressed DPED, undulating RPE line, sporadic soft drusen, and accumulation of subretinal hyperreflective deposits (Fig. 3A, B).

A year after the multimodality laser therapy the patient had no complaints. Ophthalmic examination showed that UCVA OD and OS was 0.3, BCVA OD had reached 0.9, and BCVA OS was stable (0.8). According to micropirometry, the average central retinal sensitivity OD improved to 25.7 dB, and the average central retinal sensitivity OS was stable (23.9 dB). Slit

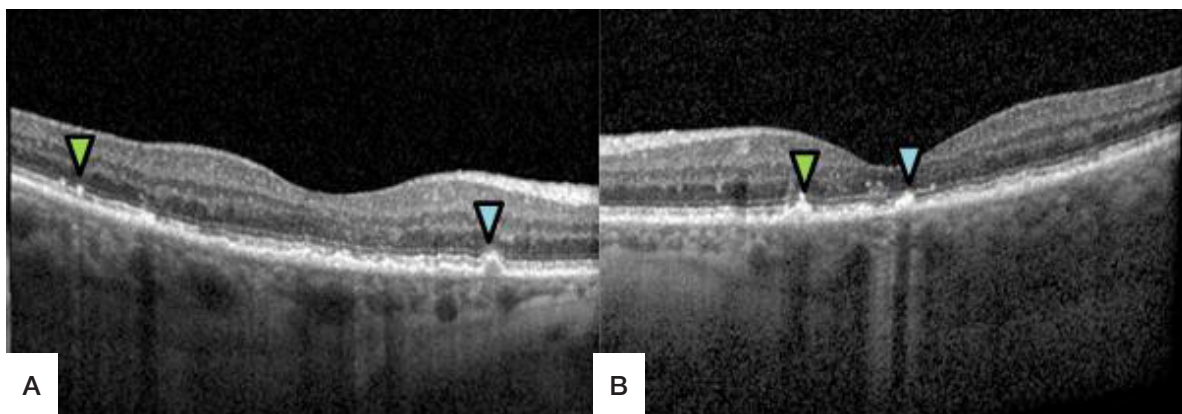


Fig. 3. Spectral-domain optical coherence tomography image of the fovea. **A.** Right eye: macula remains intact, undulating RPE line, sporadic hard drusen (blue arrow), accumulation of subretinal hyperreflective deposits (green arrow). **B.** Left eye: macula remains intact, undulating RPE line, sporadic hard drusen (blue arrow), accumulation of subretinal hyperreflective deposits (green arrow)

lamp biomicroscopy and indirect ophthalmoscopy OU revealed small yellowish round-shaped lesions with well-defined margins and redistribution of pigment in the macular zone, the lightly pigmented coagula were visible.

SD-OCT OD and OS revealed the intact macula, the integrity of retinal layers, and no evidence supporting the atrophy of the retinal outer layer and RPE.

Ophthalmic examination performed three years later showed that UCVA OD had improved to 0.4, UCVA OS had improved to 0.3, and BCVA was stable (0.9 OD, 0.8 OS, respectively). The average central retinal sensitivity OD was stable (25.7 dB), and the average central retinal sensitivity OS had improved to 24.0 dB. Slit lamp biomicroscopy and indirect ophthalmoscopy OU revealed small yellowish round-shaped lesions with well-defined margins, redistribution of pigment, and the lightly pigmented coagula in the macular zone.

SD-OCT OD and OS revealed the intact macula, the integrity of retinal layers, and no atrophy of the retinal outer layer and RPE.

Five years after the multimodality laser treatment the follow-up examination revealed stable morphological and functional effects, the patient had no complaints. Ophthalmic examination showed that UCVA OD was 0.4, UCVA OS was 0.3, BCVA OD was 0.9, and BCVA OS was 0.8. According to micropiometry, the average central retinal sensitivity OD was 24.8 dB, and the average central retinal sensitivity OS was 24.3 dB. Slit lamp biomicroscopy and indirect ophthalmoscopy OU small yellowish round-shaped lesions with well-defined margins, redistribution of pigment, and the lightly pigmented coagula in the macular zone.

SD-OCT OD and OS revealed the intact macula, the integrity of retinal layers, and no atrophy of the retinal outer layer and RPE (Fig 4A, B).

OCTA image (OU) analysis revealed no evidence supporting the choroidal neovascularization.

Clinical case discussion

Currently, there is no generally accepted treatment strategy for drusenoid pigment epithelial detachment. Literature analysis has shown that the disorder is the risk factor for AMD progression to late stage characterized by geographic atrophy, which results in the irreversible central vision loss.

A number of authors reported the cases of using photodynamic therapy with verteporfin [16], intravitreal injections of angiogenesis inhibitors [17], high-dose statin therapy [18] for treatment of DPED. These methods contributed to the reduction and regression of RPE detachment throughout the one-year follow-up period. However, the long-term efficacy and safety of the methods had not been explored.

The clinical trials on using the laser technologies in patients with the intermediate stage AMD were focused on assessing the feasibility of reducing the number of drusen and slowing the progression of the disease; in the majority of cases the follow-up period was three years. According to a number of authors, encouraging results in the form of the reduced drusen volume were achieved when using laser photocoagulation. However, side effects can develop when using the high energy laser treatment, such as photoreceptor layer death, formation of central and paracentral scotomas, progression to geographic atrophy, choroidal neovascularization, and subretinal fibrosis [10, 11]. Low power mode laser therapy was used in the reported case in order to prevent the listed above complications and provide a positive clinical impact.

Currently, a number of subthreshold laser therapy methods are used allowing one to selectively and precisely affect the RPE

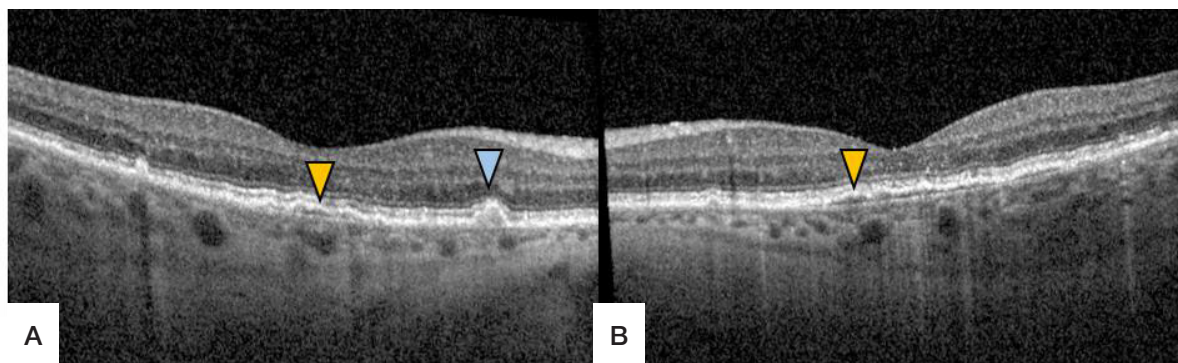


Fig. 4. Spectral-domain optical coherence tomography image of the fovea. **A.** Right eye: macula remains intact, undulating RPE line (orange arrow), sporadic hard drusen (blue arrow). **B.** Left eye: macula remains intact, undulating RPE line (orange arrow)

cells only and thus reduce the risk of adverse alterations in the retina and choriocapillaries. The use of these laser therapy methods in patients with the intermediate stage disorder reduced the number of drusen, contributed to drusen resorption and visual acuity improvement, but did not seem to have much effect in terms of slowing the disease progression to geographic atrophy or choroidal neovascularization. According to the LEAD study, no correlations between the use of laser technologies and the complications, such as retinal hemorrhages, nascent geographic atrophy, and photoreceptor layer atrophy, were revealed [12, 13].

We used a combination of two laser procedures with different mechanisms of action in order to improve the morphological and functional treatment outcome in patients with DPED. The first step was grid laser photocoagulation aimed at activating the RPE pumping function, as well as at improving the retinal architecture and enhancing the structural support provided by Muller cells through the chorioretinal adhesion creation. The use of micropulse laser therapy allowed us to selectively target the RPE cells avoiding damage to the retinal neuroepithelium. The

production of factors, maintaining and enhancing regeneration, prolonging the processes of the retinal architecture restoration and visual function improvement, was considered the main therapeutic effect.

Thus, the use of the proposed multimodality laser treatment for DPED made it possible not only to achieve good morphological and functional results, but also to maintain this level throughout the 5-year period.

CONCLUSION

The proposed multimodality laser treatment method allowed us to repair the pigment epithelial detachment (DPED), restore the retinal architecture, and improve the visual functions. The results achieved showed the potential of low-level laser microsurgery for restoring the macular morphological and functional parameters in the presence of the age-related dystrophic process. With further study, this technology may increase the potential for treatment of the intermediate age-related macular degeneration (DPED).

References

1. Wong WL, Su X, Li X, Cheung CM, Klein R, Cheng CY, Wong TY. Global prevalence of age-related macular degeneration and disease burden projection for 2020 and 2040: a systematic review and meta-analysis. *Lancet Glob Health*. 2014; 2 (2): 106–16.
2. Ferris FL, Wilkinson CP, Bird A, Chakravarthy U, Chew E, Csaky K, Sadda SR; Beckman Initiative for Macular Research Classification Committee. Clinical classification of age-related macular degeneration. *Ophthalmology*. 2013; 120 (4): 844–51.
3. Casswell AG, Kohlen D, Bird AC. Retinal pigment epithelial detachments in the elderly: classification and outcome. *British Journal of Ophthalmology*. 1985; 69: 397–403.
4. Spaide RF, Jaffe GJ, Sarraf D, Freund KB, Sadda SR, Staurenghi G, Waheed NK; Consensus Nomenclature for Reporting Neovascular Age-Related Macular Degeneration Data: Consensus on Neovascular Age-Related Macular Degeneration Nomenclature Study Group. *Ophthalmology*. 2020; 127 (5): 616–36.
5. Sarks JP, Sarks SH, Killingsworth MC. Evolution of soft drusen in age-related macular degeneration. *Eye (Lond)*. 1994; 8: 269–83.
6. Balaratnasingam C, Yannuzzi LA, Curcio CA, Morgan WH, Querques G, Capuano V, et al. Associations Between Retinal Pigment Epithelium and Drusen Volume Changes During the Lifecycle of Large Drusenoid Pigment Epithelial Detachments. *Invest Ophthalmol Vis Sci*. 2016; 57 (13): 5479–89.
7. Yu JJ, Agrón E, Clemons TE, Domalpally A, van Asten F, Keenan TD, et al. Age-Related Eye Disease Study 2 Research Group. Natural History of Drusenoid Pigment Epithelial Detachment Associated with Age-Related Macular Degeneration: Age-Related Eye Disease Study 2 Report No. 17. *Ophthalmology*. 2019; 126 (2): 261–73.
8. Roquet W, Roudot-Thoraval F, Coscas G, Soubrane G. Clinical features of drusenoid pigment epithelial detachment in age-related macular degeneration. *Br J Ophthalmol*. 2004; 88 (5): 638–42.
9. Chew EY, Clemons TE, Agrón E, Sperduto RD, Sangiovanni JP, Kurinij N, et al. Age-Related Eye Disease Study Research Group. Long-term effects of vitamins C and E, β -carotene, and zinc on age-related macular degeneration: AREDS report no. 35. *Ophthalmology*. 2013; 120 (8): 1604–11.
10. Complications of Age-Related Macular Degeneration Prevention Trial Research Group. Laser treatment in patients with bilateral large drusen: the complications of age-related macular degeneration prevention trial. *Ophthalmology*. 2006; 113 (11): 1974–86.
11. Virgili G, Michelessi M, Parodi MB, Bacherini D, Evans JR. Laser treatment of drusen to prevent progression to advanced age-related macular degeneration. *Cochrane Database Syst Rev*. 2015; 10 (10): 1–67.
12. Prahs P, Walter A, Regler R, Theisen-Kunde D, Birngruber R, Brinkmann R, Framme C. Selective retina therapy (SRT) in patients with geographic atrophy due to age-related macular degeneration. *Graefes Arch Clin Exp Ophthalmol*. 2010; 248 (5): 651–8.
13. Guymer RH, Wu Z, Hodgson AB, Caruso E, Brassington KH, Tindill N, et al. Laser Intervention in Early Stages of Age-Related Macular Degeneration Study Group. Subthreshold Nanosecond Laser Intervention in Age-Related Macular Degeneration: The LEAD Randomized Controlled Clinical Trial. *Ophthalmology*. 2019; 126 (6): 829–38.
14. Gordeeva MV, Gacu MV. Funkcional'nye rezul'taty porogovoj lazerkoaguljacii razlichnyh vidov mjadgkih makuljarnyh druz. *Vestnik OGU*. 2013; 4 (153): 59–62. Russian.
15. Gordeeva MV. Sravnenie jeffektivnosti razlichnyh lazernyh metodik lechenija mjadgkih makuljarnyh druz [dissertacija]. M., 2013. Russian.
16. Novais EA, Badaró E, Regatieri CV, Duker J, de Oliveira Bonomo PP. Regression of drusen after combined treatment using photodynamic therapy with verteporfin and ranibizumab. *Ophthalmic Surg Lasers Imaging Retina*. 2015; 46 (2): 275–8.
17. Gallego-Pinazo R, Marina A, Selves-Cogollos, Francés-Muñoz E, Millán JM, Arevalo JF, et al. Intravitreal ranibizumab for symptomatic drusenoid pigment epithelial detachment without choroidal neovascularization in age-related macular degeneration. *Clin Ophthalmol*. 2011; 5: 161–5.
18. Vavvas DG, Daniels AB, Kapsala ZG, Goldfarb JW, Ganotakis E, Loewenstein JI, et al. Regression of Some High-risk Features of Age-related Macular Degeneration (AMD) in Patients Receiving Intensive Statin Treatment. *EBioMedicine*. 2016; 5: 198–203.

Литература

1. Wong WL, Su X, Li X, Cheung CM, Klein R, Cheng CY, Wong TY. Global prevalence of age-related macular degeneration and disease burden projection for 2020 and 2040: a systematic review and meta-analysis. *Lancet Glob Health*. 2014; 2 (2): 106–16.
2. Ferris FL, Wilkinson CP, Bird A, Chakravarthy U, Chew E, Csaky K, Sadda SR; Beckman Initiative for Macular Research Classification Committee. Clinical classification of age-related macular degeneration. *Ophthalmology*. 2013; 120 (4): 844–51.
3. Casswell AG, Kohlen D, Bird AC. Retinal pigment epithelial detachments in the elderly: classification and outcome. *British Journal of Ophthalmology*. 1985; 69: 397–403.
4. Spaide RF, Jaffe GJ, Sarraf D, Freund KB, Sadda SR, Staurengi G, Waheed NK; Consensus Nomenclature for Reporting Neovascular Age-Related Macular Degeneration Data: Consensus on Neovascular Age-Related Macular Degeneration Nomenclature Study Group. *Ophthalmology*. 2020; 127 (5): 616–36.
5. Sarks JP, Sarks SH, Killingsworth MC. Evolution of soft drusen in age-related macular degeneration. *Eye (Lond)*. 1994; 8: 269–83.
6. Balaratnasingam C, Yannuzzi LA, Curcio CA, Morgan WH, Querques G, Capuano V, et al. Associations Between Retinal Pigment Epithelium and Drusen Volume Changes During the Lifecycle of Large Drusenoid Pigment Epithelial Detachments. *Invest Ophthalmol Vis Sci*. 2016; 57 (13): 5479–89.
7. Yu JJ, Agrón E, Clemons TE, Domalpally A, van Asten F, Keenan TD, et al. Age-Related Eye Disease Study 2 Research Group. Natural History of Drusenoid Pigment Epithelial Detachment Associated with Age-Related Macular Degeneration: Age-Related Eye Disease Study 2 Report No. 17. *Ophthalmology*. 2019; 126 (2): 261–73.
8. Roquet W, Roudot-Thoraval F, Coscas G, Soubrane G. Clinical features of drusenoid pigment epithelial detachment in age related macular degeneration. *Br J Ophthalmol*. 2004; 88 (5): 638–42.
9. Chew EY, Clemons TE, Agrón E, Sperduto RD, Sangiovanni JP, Kurinij N, et al. Age-Related Eye Disease Study Research Group. Long-term effects of vitamins C and E, β -carotene, and zinc on age-related macular degeneration: AREDS report no. 35. *Ophthalmology*. 2013; 120 (8): 1604–11.
10. Complications of Age-Related Macular Degeneration Prevention Trial Research Group. Laser treatment in patients with bilateral large drusen: the complications of age-related macular degeneration prevention trial. *Ophthalmology*. 2006; 113 (11): 1974–86.
11. Virgili G, Michelessi M, Parodi MB, Bacherini D, Evans JR. Laser treatment of drusen to prevent progression to advanced age-related macular degeneration. *Cochrane Database Syst Rev*. 2015; 10 (10): 1–67.
12. Prahs P, Walter A, Regler R, Theisen-Kunde D, Birngruber R, Brinkmann R, Framme C. Selective retina therapy (SRT) in patients with geographic atrophy due to age-related macular degeneration. *Graefes Arch Clin Exp Ophthalmol*. 2010; 248 (5): 651–8.
13. Guymer RH, Wu Z, Hodgson AB, Caruso E, Brassington KH, Tindill N, et al. Laser Intervention in Early Stages of Age-Related Macular Degeneration Study Group. Subthreshold Nanosecond Laser Intervention in Age-Related Macular Degeneration: The LEAD Randomized Controlled Clinical Trial. *Ophthalmology*. 2019; 126 (6): 829–38.
14. Гордеева М. В., Гацу М. В. Функциональные результаты пороговой лазеркоагуляции различных видов мягких макулярных друз. *Вестник ОГУ*. 2013; 4 (153): 59–62.
15. Гордеева М. В. Сравнение эффективности различных лазерных методик лечения мягких макулярных друз [диссертация]. М., 2013.
16. Novais EA, Badaró E, Regatieri CV, Duker J, de Oliveira Bono PP. Regression of drusen after combined treatment using photodynamic therapy with verteporfin and ranibizumab. *Ophthalmic Surg Lasers Imaging Retina*. 2015; 46 (2): 275–8.
17. Gallego-Pinazo R, Marina A, Suelves-Cogollos, Francés-Muñoz E, Millán JM, Arevalo JF, et al. Intravitreal ranibizumab for symptomatic drusenoid pigment epithelial detachment without choroidal neovascularization in age-related macular degeneration. *Clin Ophthalmol*. 2011; 5: 161–5.
18. Vavvas DG, Daniels AB, Kapsala ZG, Goldfarb JW, Ganotakis E, Loewenstein JI, et al. Regression of Some High-risk Features of Age-related Macular Degeneration (AMD) in Patients Receiving Intensive Statin Treatment. *EBioMedicine*. 2016; 5: 198–203.